

## Intra-Articular Injection of an Extracellular Vesicle Isolate Product to Treat Hip Labral Tears

JohnnyEast DO and Maxwell Dordevic\*

Addison Pain & Regenerative Medicine, 16633 Dallas Pkwy Suite 150, USA

\***Corresponding Author:** Maxwell Dordevic, Addison Pain & Regenerative Medicine, 16633 Dallas Pkwy Suite 150, USA, Tel: 5039281210; E-mail: mdordevic@utexas.edu

**Received Date:** 09-18-2019; **Accepted Date:** 09-26-2019; **Published Date:** 10-1-2019

**Copyright** © 2019 by Maxwell Dordevic, et al. All rights reserved. This is an open access article distributed under the terms of the Creative Commons Attribution License, which permits unrestricted use, distribution, and reproduction in any medium, provided the original author and source are credited.

### Keywords

Hip Joint; Triathlete; Hip Labral Tears; Mesenchymal Stem Cell; Evip Injection

### Introduction

Diarthrodial joints, such as the knee, hip, and shoulder consist of articular cartilage, a synovial capsule, and a fibrocartilaginous structure to increase the stability of the joint. The knee has both a medial and lateral meniscus. The patient's shoulder and hip each have a labrum which increases the concavity of the glenoid and acetabulum. These fibrocartilaginous structures all have a nerve supply and when torn, can be very painful. These structures have a limited blood supply and when damaged, have minimal capacity to heal. These structures can tear with an acute injury or by a chronic degenerative process [1]. The acetabular labrum creates a fibrocartilaginous seal around the osseous acetabulum. The labrum increases the depth, surface area, volume, congruity, and stability of the hip joint. The labrum has been shown to increase by an average of 22 % to the articulating surface area of the hip joint [2]. The labrum lowers the stress on the articular cartilage by regulating fluid transport between the central and peripheral compartments and by distributing contact pressure across the articulating surfaces [3]. This fluid seal is one of the most important function of the labrum, as it produces a negative intra-articular pressure, significantly increasing joint stability [4].

If the shape of the femoral head and acetabulum do not perfectly match, femoral-acetabular impingement can occur. This is a genetic condition that predisposes the hip labrum to traumatic injury. Hip labral tears are associated with certain activities such as gymnastics, running, jumping, tennis, soccer, and cycling. The diagnosis is suspected when hip ROM,

especially forced flexion with internal rotation duplicates the groin pain the patient typically experiences. The diagnosis is confirmed with MRI scanning.

There is a paucity of non-operative treatments for hip labral tears. The most common and effective solution includes decreasing or avoiding activities that causes pain. Physical therapy has shown little efficacy. Surgical options are typically performed arthroscopically. The surgical options include either repairing the labral tear or, more commonly, resecting the torn labrum [1]. Krych, et al, reported the results of hip arthroscopic treatment for labral tears. They reported 59 patients, the mean age was 46, and the mean follow up was 5 years. They reported a clinical failure rate of 45% due to repeat surgery in 20% and continued pain in 25% [5].

Published reports of using injections of autogenous bone marrow concentrate (BMC) with mesenchymal stem cells (MSC) to treat shoulder labral tears indicate safety and efficacy [6]. The MSC is the only cell that can differentiate into a chondroblast, osteoblast, or fibroblast [7-12]. It has historically been thought differentiation was the mechanism by which MSC injections treated joint pathology [13-19]. It has become increasingly recognized the efficacy of using MSC injections to treat various conditions is due to their paracrine function of releasing anti-inflammatory growth factors (GF) and exosomes [16,17]. These GFs and exosomes can be injected without any living cells [12-15]. This case report will introduce the concept of using acellular bone marrow-derived MSC GFs and exosomes to treat hip labral tears. This is described as an extracellular vesicle isolate product (EVIP). The paper will discuss the rationale of why acellular will replace all current cellular biologic therapies, both autogenous and allogeneic for the treatment of various joint pathologies.

## Materials and Methods

This is a case report of an EVIP injection for the treatment of a hip labral tear. A hip labral tear is characterized by a locking, clicking, or catching in the hip joint. Pain is felt in the groin or radiating into the trochanteric area. Patients complain of stiffness or limited hip range of motion. MRI scanning is used to diagnose a labral tear of the hip joint. The patient is a 50-year old, extremely active triathlete, personal trainer, and health instructor. Following several months of untreated groin pain, she presented on 6/11/2019 with an increasing right groin and buttocks pain radiating into the upper leg. Her symptoms were exacerbated with activities requiring hip ROM. MRI scanning of the hip joint on 6/4/19 revealed a superior labrum tear, superior anterior labral fraying, tear of the gluteus minimus tendon, trochanteric bursal inflammation, and common hamstring tendinosis. The hip joint did not have osteoarthritis. She had been treated with NSAIDs, weekly active release, and chiropractic treatments. On physical examination she had an overall 20% loss of hip ROM. Forced internally rotation and flexion replicated and severely exacerbated her pain. The patient felt overall her right hip was less than 50% normal compared to the opposite hip.

The patient was evaluated with a Brief Pain Inventory (BPI), a Lower Extremity Functional Index (LEFI), and an Oswestry Disability Index (ODI) prior to the injection and at follow-up.

## The hip injection

After counseling and consent, the patient on 6/11/2019 underwent the hip injection. The right groin and buttocks area were sterilized with a betadine skin prep. A 20-gauge needle was placed through an anterior approach into the hip joint. Needle placement was verified by fluoroscopy. At this point, 2cc of the frozen EVIP (ExoFlo-Direct Biologics, St. Louis MO) was thawed to room temperature and placed into the joint.

## Clinical Results

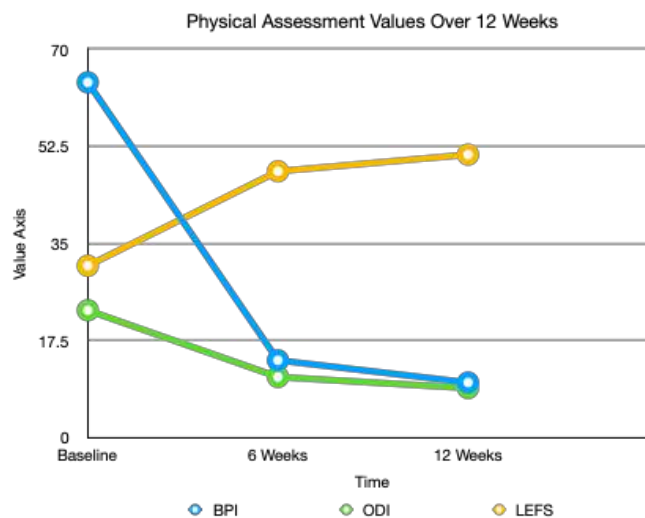
The patient was put on restricted physical activity for 1 week following the procedure. Passive low-resistance range of motion was encouraged immediately. The patient returned to full activities at 10 days. Six weeks post-procedure, she was able in one day to run 7 miles, kayak 2 hours and swim 600 yards. She was able to sleep like a “rock” and wake up with no pain. The patient opines she has experienced an overall 75% improvement from her pre-procedure hiplabral tear symptoms.

## Follow Up MRI Scan

A follow-up gadolinium arthrogram MRI scan of the right hip was performed on 8/28/2019. The scan showed NO discrete labral tear. There was no evidence of tendinosis or interstitial tearing of the gluteus minimums tendon. There was no trochanteric bursal inflammation. The impression was a negative MRI of the right hip joint.

Her clinical results from pre-procedure to 12-week FU are shown in both (Figure 1) and (Table 1). They detail the improvement noted in her Brief Pain Inventory (a lower score is better), Oswestry Disability Index (a lower score is better), and her Lower Extremity Functional Score (a higher score is better).

**Figure 1:** A lower BPI and ODI=improvement, a higher LEFS score=improvement.



**Table 1:** Physical evaluation measurements with the percent improvement over the initial 12 weeks.

	<b>Baseline</b>	<b>6 Weeks</b>	<b>12 Weeks</b>	<b>Percent Improvement</b>
<b>BPI</b>	64	14	10	84%
<b>ODI</b>	23	11	9	61%
<b>LEFS</b>	31	48	51	61%

## **Discussion**

The patient is an active 50 YO triathlete with a history of increasing pain from a documented hip labral tear. She underwent a single anterior hip injection of 2cc of bone marrow-derived mesenchymal stem cell EVIP (ExoFlo-Direct Biologics, St. Louis MO) containing active growth factors and exosomes. Two weeks later, her labral tear symptoms were improved by 75%. This improvement has been maintained through three months. Her pre-injection arthrogram MRI documents a superior labrum tear, superior anterior labral fraying, tear of the gluteus minimus tendon, trochanteric bursal inflammation, and common hamstring tendinosis. The hip joint did not have osteoarthritis. Her post-injection arthrogram MRI documents no evidence of a labral tear. There was no evidence of tendinosis or interstitial tearing of the gluteus minimus tendon. There was no trochanteric bursal inflammation. The impression was a negative MRI of the right hip joint. She will continue to be closely monitored for two years.

The non-operative treatment for symptomatic labral tears is basically to avoid activities that cause pain. The surgical options are either arthroscopic removal or repair of the labrum [1]. Published results indicate a 45% failure rate with arthroscopic hip labral surgery [5].

There is increasing published literature on the use of bone marrow concentrate (BMC) to treat joint OA [7-11]. Bone marrow-derived MSC therapy is standard of care in veterinary medicine. There is increasing interest in using biologics to potentially heal fibrocartilaginous injuries in the shoulder, knee, and hip to avoid surgery. Chew et al. published a literature review in 2017 on using MSCs for meniscal regeneration and found four published papers [18]. However, only one study included class one data [19]. Chew concluded “the limited number of human studies has suggested that stem cells do have potential to undergo meniscal regeneration in humans and there is reason to be optimistic for the future.”

## What is the mechanism by which an EVIP injection can regenerate and heal a torn hip labrum?

Based on understanding the biology of labral tears, non-operative treatment will be an injection of acellular MSC derived growth factors and especially exosomes. The exosome is a tiny 30 to 150 nanometer-sized (1 billionth of a meter) bi-phospholipid membrane-enclosed structure created by the endosomes. An MSC (12 to 18 microns) is 1,000 times larger than an exosome. The diameter of a hair is 80,000 nanometers. Exosomes contain growth factors, signaling lipids and micro, and messenger RNA. These paracrine factors can be placed into any joint in concentrations of 100,000 or more times that of any cellular MSC treatment. These growth factor proteins and exosomes function in a paracrine fashion to both, directly and indirectly, alter the inflammatory environment of a painful labral tear back to a normal non-painful physiologic environment and stimulate fibrocartilaginous healing [12-15].

The future acellular treatment for labral tears will involve a two-step process: first, highly concentrated anti-inflammatory bone marrow-derived MSC growth factors and exosomes are injected into the painful joint. Second, these growth factors and exosomes enter the recipient synovial MSCs to stimulate the production of new chondroblasts and anti-inflammatory secretomes, chemokines, and cytokines. These effects have been shown to heal fibrocartilaginous tears [18,19]. This acellular biologic treatment can all be achieved with a single joint injection. The future of regenerative medicine in orthopedics and spine may well be the utilization of highly concentrated acellular MSC derived growth factors and especially EXOSOMES [12-15].

## References

1. Harris JD. Hip labral repair: options and outcomes. *Curr Rev Musculoskelet Med.* 2016;9(4):361-367.
2. Seldes RM, Tan V, Hunt J, Katz M, Winiarsky R, Fitzgerald RH Jr. Anatomy, histologic features, and vascularity of the adult acetabular labrum. *Clin Orthop Relat Res.* 2001;382:232-40
3. Dwyer MK1, Jones HL, Hogan MG, Field RE, McCarthy JC, Noble PC. The acetabular labrum regulates fluid circulation of the hip joint during functional activities. *Am J Sports Med.* 2014;42(4):812-9.
4. Philippon MJ, Nepple JJ, Campbell KJ, Dornan GJ, Jansson KS, LaPrade RF, et al. The hip fluid seal—part I: the effect of an acetabular labral tear, repair, resection, and reconstruction on hip fluid pressurization. *Knee Surg Sports Traumatol Arthrosc.* 2014;22(4):722-9.
5. Krych AJ, Kuzma SA, Kovachevich R, Hudgens JL, Levy BA. Modest Mid-term outcomes after Isolated Arthroscopic Debridement of Acetabular Tears. *Knee Surg Sports Traumatol Arthrosc.* 2014;22(4):763-7.
6. Beitzel K, Solovyova O, Cote MP, Apostolakis J, Russell RP, McCarthy MB, et al. The future Role of Mesenchymal Stem Cells in the Management of shoulder Disorders. *Arthroscopy.* 2013;29(10):1702-11
7. Zhao L, Kaye AD. Stem Cells for the Treatment of Knee Osteoarthritis: A Comprehensive Review. *Pain Physician.* 2018;21:229-241
8. Black LL, Gaynor J, Adams C, Dhupa S, Sams AE, Taylor R, et al. Effect of intraarticular injection of autologous adipose-derived mesenchymal stem and regenerative cells on clinical signs of chronic osteoarthritis of the elbow joint in dogs. *Vet Ther.* 2008;9:192-200.
9. Pettine KP, Suzuki R. Autogenous Bone Marrow Concentrate for the treatment of osteoarthritis of the knee, hip and shoulder in former NFL players. *J Stem Cell Res Ther.* 2018;4(1):9-13.
10. Freitag J, Bates D. Mesenchymal stem cell therapy in the treatment of Osteoarthritis: reparative pathways, safety, and efficacy: A Review. *BMC Musculoskeletal Disorders.* 2016;17:230.

11. Pettine KP, Dordevic M. Tibial Metaphyseal Injection with Bone Marrow Concentrate to Treat Knee Arthritis. *American J Stem Cell Res Ther.* 2018;2(1):5-10
12. Li Z, Wang Y, Xiao K, Weng X. Emerging Role of Exosomes in the Joint Diseases. *Cell Physiol Biochem.* 2018;47(5):2008-2017.
13. Pettine KP, Dordevic M. The Biologic Treatment of Osteoarthritis with Mesenchymal Stem Cell Exosomes: The Future is now. *J Stem Cell Res Dev Ther.* 2019;1-5.
14. Cheng L, Zhang K, Wu S, Cui M, Xu T. Focus on Mesenchymal Stem Cell-Derived Exosomes: opportunities and Challenges in Cell-Free Therapy. *Stem Cells Int.* 2017;2017:6305295.
15. Zhang S, Chuah SJ, Lai RC, Hui JHP, Lim SK, Toh WS. MSC Exosomes Mediate Cartilage Repair by Enhancing Proliferation, Attenuating Apoptosis and Modulating Immune Reactivity. *Biomaterials.* 2018 Feb;156:16-27.
16. Caplan AI, Correa D. The MSC: An injury drugstore. *Cell Stem Cell.* 2011 Jul 8;9(1):11-5.
17. Caplan AI, Dennis JE. Mesenchymal stem cells as trophic mediators. *J Cell Biochem* 2006;98:1076-1084.
18. Chew E, Prakash R, Khan W, Mesenchymal Stem Cells in Human Meniscal Regeneration: A Systemic Review. *Ann Med Surg.* 2017;24:3-7
19. Vangsness CT, Farr J, Boyd J, Dellaero. Adult human mesenchymal stem cells delivered via intra-articular injection to the knee following partial medial meniscectomy: a randomized, double-blind controlled study. *JBJS.* 2014:90-98.